



Gardali

Advanced Restorative

ImplantONE™

Gardali-EstheticZONE™

World-Class Restorative Solutions



EstheticZONE Newsletter, Volume 14

QTR. 3 / 2025



THE TRUTH ABOUT AUTHENTIC CUSTOM ABUTMENTS!

The **TRUTH** of the matter is ANY off-brand abutments simply **ARE NOT** worth the risk! "Reverse" engineering is not a 100% match. Implant companies spend MILLIONS on research & development, engineering and production to create a zero-tolerance abutment. AND they warranty and "back-it"!

An off-brand abutment can contribute to **Peri-Implantitis!** This can occur with micro-movement over time OR chairside due to cement in the sulcus

(That's why we recommend screw-retained) or poor patient care. Let's do all we can to avoid this. **AUTHENTIC** custom abutments mitigate this risk!

What is the deeper TRUTH??? This is beyond optimal patient care...It is about **LIABILITY!** Even though a vendor "guarantees" their abutment...You do NOT want to end up in court for a major implant failure and have the implant vendor NOT support you. And they will NOT if you do not use **AUTHENTIC** components. Period. Don't believe me? Ask you implant rep. AND...I am not talking about a free abutment & crown...I am referring to **LAWSUITS**. It's not worth the \$200 savings.

So, why do laboratories offer such a thing?

See details by scanning the Q-code below!

PROFITS! Laboratories retain far more profit offering a 3rd party, off-brand **CHEAP**, custom abutment...even after the typical discount is extended. We simply will NOT do that.

So, why choose Gardali Advanced restorative & ImplantONE?

- **Our Team:** Benjamin, our Implant expert has restored well over **10,000** implants! Ben's experience is unmatched regarding the critical factors to consider when restoring an implant-supported case.
- **Having a deep understanding of each specific implant system.** Every case is unique and so are implant companies and the components they offer. Benjamin will help you navigate these treacherous conditions.
- **AUTHENTIC** Custom abutment design that maximizes the outcome and often times can mitigate challenges chairside!
- **Digitally Designed / Artisan Perfected:** Why put a rudimentary, possible AI designed crown on the ideal abutment! **TRUST:** Do you **TRUST** your Dental Laboratory? work is done **IN THAT** facility? **TRUST** is critical!
- **Communication:** Does your laboratory communicate well with your team?

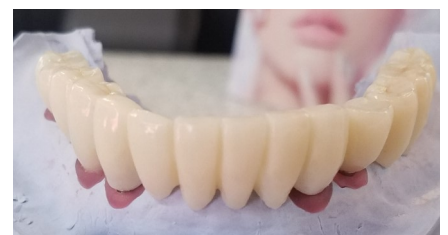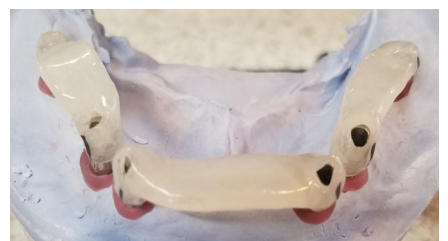We have much more to share about these topics....
Scan the Q-Code to get the **WHOLE TRUTH!**

Paul C. Intino, Owner/President



In This Issue:

- The **TRUTH...**about **AUTHENTIC** abutments!
- Implant **EXPERT** Tip.
- From the desk of Paul Intino, Owner.



"Gardali has been a significant member of my team for 30 yrs. I value Gardali's technical & materials knowledge to assist in decision making to optimize patient outcomes"

Dr. Brian Jackson. Utica, NY

ImplantONE / Expert tip!

Implant Location / CRITICAL.

Proper incisocervical, occlusocervical, and faciolingual positioning of implants promotes the development of restoration contours that transition from the round form of the implant to the desired tooth form. These transitional contours allow the artificial replacement to possess a normal profile when it emerges from the soft tissue. Proper implant positioning also promotes the development of normal soft tissue form and location.

Location For Single Crowns:

The implant should be centered mesiodistally in the edentulous space for esthetic reasons (Figure 1A). Centering the implant facilitates the development of normal proximal emergence profile, permits better morphologic replication of the contralateral tooth, and prevents the replacement tooth from appearing tilted in the arch (Figures 16A, 16B). Faciolingually, the implant should be located at the center of the edentulous space or be located slightly to the facial. A position slightly to the facial can sometimes be advantageous when the existing bone dimensions permit (Figure 1A) since centering the implant may produce a crown with a deficient cervical contour (Figures 17A, 17B) or a crown where porcelain must overlap the facial soft tissue to create the desired cervical crown morphology (Figures 18B). Overlapping the soft tissue makes oral hygiene more difficult, and it presents an esthetic liability should the soft tissue position recede apically. **Read the complete piece at GardaliLab.com**

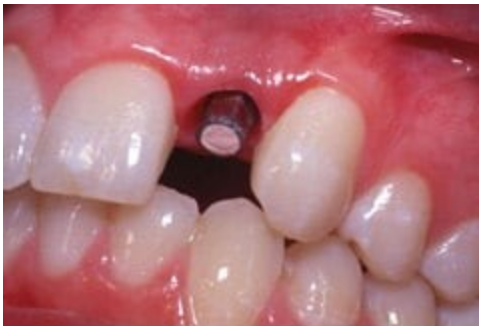

Figure 1A

There is plenty of space between the prefabricated abutment and the opposing tooth for placement of a metal ceramic crown with an esthetic thickness of porcelain overlying the metal casting. The implant was placed so it was centered mesiodistally in the available space between the adjacent teeth.

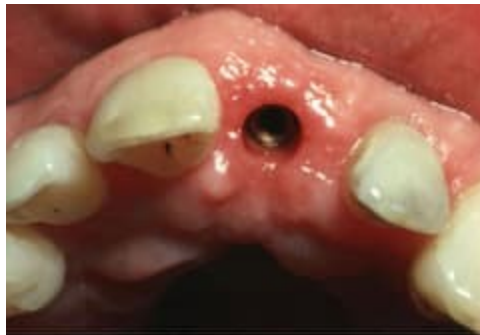

Figure 16A

The maxillary central incisor implant was placed too far mesially.

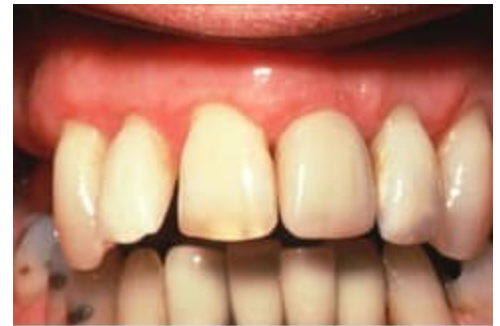

Figure 16B

Even with create shaping, the central incisor crown appears to be tilted in the arch.

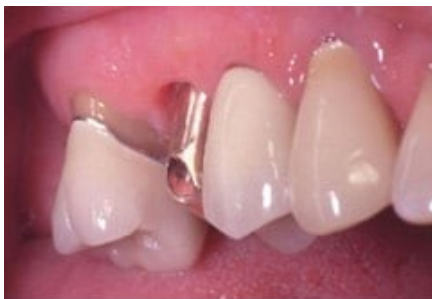

Figure 17A

The maxillary second premolar implant was centered faciolingually in the edentulous ridge. Sometimes this location is a result of the facial ridge resorption that occurs following tooth extraction and other times it is a result of less than optimal surgical placement.

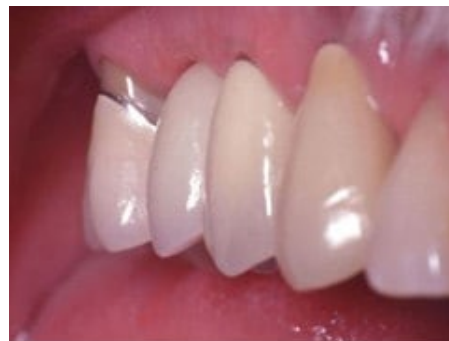

Figure 17B

Because of the centered position of the implant, the crown is undercontoured relative to the cervical form of the adjacent natural teeth.

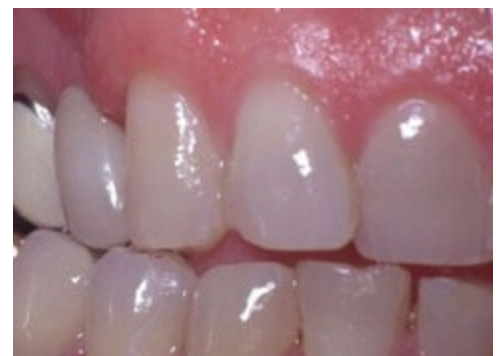

Figure 18B

The lingual position of the implant required the facial porcelain to overlap the soft tissue much like the pontic of a fixed partial denture overlaps the edentulous ridge mucosa. The overlapping of the soft tissue produces an acceptable esthetic result but creates oral hygiene challenges and would produce an esthetic liability if the mucosa ever recedes apically.

Thank-you Doctor,
Paul C. Intino, Owner / President

From the desk of Paul Intino, owner.

Dear Doctor,

First let me take a moment and thank you and your team for **TRUSTING** us with your patient's smiles! We take our work very serious and are passionate about providing you with the very best restorations possible.

Is it **QUALITY, PREFERENCES** or what to do (and NOT do) to avoid typical chairside challenges???

“Quality is a moving target”. WHY? Dentistry from chair to laboratory is NOT a perfect science. AND NO...not even with IOS and the digital world. AND, let's NOT discuss Ai, yet!

How can we mitigate the typical challenges we face?

MARGINS: Naturally, we all want sealed margins. NOT only for a nice fit however, to mitigate/eliminate any micro leakage that can lead to reoccurring decay. Where does the problem start? It can start with the prep. Is the margin clearly defined? Is it a feather/knife edge or a shoulder for a Zirconia crown? Is it sub-G & did you share that on the RX? AND now we impress. Did the impression pick-up the margin clearly ALL the way around the tooth? Did you pack cord? Was the environment dry? If you utilize IOS, it is not a magic wand! The scan does NOT go through blood, tissue a saliva and keep in mind, you have NO material moving that out of the way. Can YOU see the margin clearly on the IOS screen? If you cannot...neither can we.

CONTACT: The challenge with quality can be easily demonstrated by contacts. Each Doctor has a different perspective on the ideal contact. Some want them “light” so they seat without much time to adjust. Some want them “broad & heavy” for they realize there will be adjacent tooth movement and better to error heavy/tight than light/open. WHY? You can adjust the heavy/tight contacts and the patient leaves with teeth and pays for the care. Light/open means we just wasted everyone's time...mostly YOURS. Patient goes home toothless, case goes back to the lab and we all enjoy the extra work for \$0.00 just to aggravate the patient. We error on the side of heavy/broad & tight to keep YOU out of that situation. **Agree???** What about non-ideal adjacent teeth creating only the possibility of a pin point contact near the incisal 1/3?? THIS happens every day. Can we give you a contact reduction coping?? We can then give you the nice broad contact we all want. (See image below)

Why do we have tight/ideal contacts on the model and NOT in the mouth? Temporization is typically the culprit here. Temporizing in a strong contact will move the adjacent teeth. In a typical 2-3 week seating visit moving teeth fractions of a millimeter is just enough to OPEN your contacts. Temporize lightly in contact to mitigate this risk.

OCCLUSION: So much to discuss and too little space. I will share this: In MOST cases triple trays are the problem. Why? NOT enough data captured, NO cross-arch reference to stabilize / identify a bite, patient bites “weird” for they only have material on ONE side of their mouth, the trays flex and rebound causing a discrepancies right for the beginning and the patient bites the tray. AND, when scanning (in-lab) a triple tray model is more difficult to translate to digital. **FULL ARCH** solves all these issues. Secondly, bite was taken POST prep. The patient “squeezes” their occlusion into that created space. This is inaccurate. Take the bite (a real bite registration!) PRIOR to tooth preparation. Also, consider this... articulation sometimes can be challenging. If you take a full-arch...do BOTH arches. Articulating a full-arch to an opposing quadrant is difficult. Finally, (If taking bite post prep) remove cotton rolls and dry angles when taking the bite. The patient may not bite accurately with them in place.

SHADE / CHARACTERIZATION: Shade is far more than just “Shade”. Hue, Chroma, Value, any **unique** characteristics of adjacent teeth and gingiva! ALL anterior cases REQUIRE a photo of the patient. We want to see the adjacent teeth. MOST shade adjustments can be eradicated by simply providing a photo. When we have a shade adjustment and NO photo provided there is an adjustment fee.

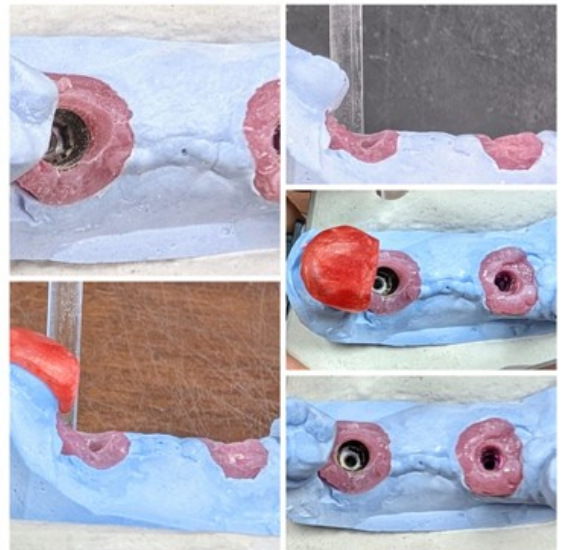

What's next? Call or visit us online to request a Doctor Resource Kit.

Thank YOU and take care,

Paul Intino, Owner.

Paul@GardaliLab.com

315.732.8204





Gardali

Advanced Restorative

ImplantONE™

When it matters most... **TRUST** Gardali! | GardaliLab.com



When it matters most **TRUST** Gardali Advanced Restorative / Implant**ONE**!